Ann. For. Res. 66(1): 738-748, 2023
ISSN: 18448135, 20652445
ANNALS OF FOREST RESEARCH
www.e-afr.org

HISTOLOGICAL STUDY OF OVARIAN FOLLICLES AND CLASSIFICATION OF ATRETIC IN ADULT FEMALE BLACK GOAT

Saif A. Muhson and Baraa Qassim Dawood
Department of Anatomy and Histology, College of Veterinary Medicine, University of Baghdad, Iraq

Abstract:
The present study aimed to study ovarian follicles growth and the degezative of the ovarian follicles in the Iraqi Black goat. eight ovaries collected from the different part of Iraqi market.for the histological process all the samples fixed in neutral buffer formalin 10%. The Histological section were prepared by using parafin section with rotary microtome & thickness 5mm while staining procedure Hematoxyline and eosin stain, to determine and detect histological structure of the cortex & medulla and classified the follicles type in the ovarian mass. Histological result showed cortex layer of ovary outer surface tunica albuginea, connective tissue covering the outer surface of the ovary in the cortex layer contains different type of follicles of various stage of follicles developments primordial contain a single layer of oocyte surrounded by single layer of the granulosa cell . primary follicles surrounded by a single layer of the granulosa cell. Secondary follicles characterized by present two or more layers of granulosa cell . Antral follicles filles with follicular fluid in the antral cavity. Antrum very large and clear in graffian follicles. Medulla appears & lined by loose connective tissue and different type of blood vessels. The mean thickness of the cortex 189.512±1.15mm and medulla 94.21±1.21 mm, the diameters of Primordial 63.865±2.02mm,primary 86.21±2.03mm, secondary 166.22±11.2mm and graffian 488.22±11.2mm. Atretic follicles in goat characterized by universal phenomenon process by degenerative morphological changes in granulosa cell & theca cells incarrent study classified the atretic follicles into three types (aninitial atresia, cystic atretic, obliterated atretic) with luteinization of the granulosa cells. **Conclusion:** The Result of this study referring to the histological structure of the ovary in the female genital system of goat.The atretic follicles were almost identical and these were characterized by presence of antrum and the granulosa cell notice droped and separated from each other into the antrum according to the type of atretic follicles.
Key wards: Goat, Ovary, Follicles growth, Atretic follicles

Introduction:

The goat, often known as the domestic goat (Capra hircus), Geographical distribution of goat in the world present in Asian and African (Smith and Sharman, 2009). According to the United Nations, there were more than 924 million goats in the world in 2011. The ovaries, which are the female reproductive organs, are a small, longitudinal, oval located in the caudal of the kidneys in the abdominal cavity (Dyce et al., 2010; Shively,1984). Ovaries are connected by their mesovarium, which is the cranial part of the broad ligament of the uterus, which connects the reproductive organs to the abdominal wall and is a peritoneum wrap(Alwan, .2014).. Ovaries are found in the ovarian bursa, which formed by the mesosalpinx externally, the mesovarium with the round ligament of the ovary and the mesovarium internally. It consists of two parts in the ovary:

cortex on the outside and medulla on the inside (huqu *et al*., 2015). In all mammals except for mare, the cortex settles in the periphery. The structure of the cortex and medulla is very variable according to the stages of the sexual cycle, age, and type (Özer, 2010). Ovarian tissue is surrounded by surface epithelial cells that change from outer to cuboidal to flattened, and this area is called stratum germinal epithelia (Al-Khazraj ,*etal*.,2016) . The cells in this area are also called germinative epithelium (Dyce et al .,2010). Germinative epithelial cells can be cubicprismatic in developing females, prismatic in adults and flattening epithelium at later ages (Jennigs et al ., 2017 ; Özer, 2010) Under the stratum germinatal tunica albuginea is found with connective tissue (Banks, 1993 ; William, 1986). In most mammalian species, cortex and medulla can be distinguished. The cortex forms the follicles at different stages of development and the reticulum threads with collagen surrounding them (Kaymaz et al., 2013). The medulla consists of blood vessels, lymph vessels, nerves, elastic, and reticular connective tissue fibers (Banks, 1993; McEntee, 1990). Follicles are fluid-filled, blister-like structures that have developing oocytes (Bari., etal.2011) and most of the follicles degenerate during their growth and maturation. Antral follicles surged by the folliclestimulating and luteinizing hormone for ovulation and, the rest of that follicles change their histological structure through degeneration (Kennedy.,*etal*.1974), the Follicles number and their types vary between mammal species, and within the same species
The present study aimed to study the development and degeneration of ovarian follicles in goat Also, to study histological and histochemical structure of the goat ovary

Material and method

The Animals: in This study were conduct on Twelve healthy female Iraqi black goats more than 7 months and their weight between 10-12 kg for All the goats were buy from the Iraqi market. The ovaries observed in the abdomen during surgical operations.The position in situ and the connections of the ovaries with ligaments observed and registered. Then after removed the ovaries from the body observed and recorded the following indices:

1. The shape of the ovaries
2. The length, weight and diameters of ovaries were measured by using digital caliper electrical balance and all measurements were recorded in millimeters. The measurements of the ovary determined according to Songsasen et al., 2009). as the following :

a. The length was measured from end to end of ovary along an axis parallel to the ovarian mesenteric attachment fig …
b. The diameters was measured as the distance of axis around the ovarian mass

3. The weight of both ovaries measured by using a sensitive electric balance and recorded in gram. (Haibat and Rabie.,2019)

Histological examinations: Tissue samples for histological examination were collected from each animals immediately after obtaining gross morphology data, processing the samples for histological technique and staining process: Under light microscope, five sections of each specimen the ovaries Histomorphometrical and histological technique determination was taken by

multiple measurements (N=6) of each section using ocular stage micrometer at 40x and 10 x magnification (Luna, 1968).

Histological finding

Sequence steps of the overies for mature goat was studies the ovary has distingneshed for two region cortex and medulla,the oocyte and primordial cells distributes in the germinal epithelia of the cortex for different stage for irregular shape for different stage of development while granulosa cell appear surrounding the primordial follicles (fig.1)

In the cortex have many type of follicles on the outer surface of the ovary show as well developed radially orientation oocyte. the ovaries mass called parenchyma tissue Primordial follicles appear as a smallest and simplest structure consist of primary oocyte surrounded by a single layer of flattened granulosa cell rested on the basal lamina (fig.2,3)

In the cortex showed primary follicles large in size compare with primordial ,each primary follicles consist of primary oocyte surrounded by single layer of cuboidal follicles epithelium in secondary follicles oocyte surrounded by granulosa cells multiple later based on zona pellucida (fig.3,4)

Mean dimension of the ovarian structures at different regions of ovarian layer shown in Table 1

The ovary in the goat show medulla region, it consisted of loose connective tissue, tortuous blood vessels, lymphatic vessels, nerve fibers and coiled arteries called helicrine arteries. (fig.9)

The granulosa cells multiply to create several layers around the oocyte. Between the oocyte and the granulosa cells, a boundary layer known as the zona pellucida forms. The follicle's stromal cells undergo theca interna and theca externa differentiation. After the layers of granulosa cells separate other to produce the a fluid-filled space or antrum. The clump of granulosa cells which continue to encirclethe follicle is named the cumulus oophorus, Corona radiata refers to the cumulus oophorus cells that are directly around the oocyte. (fig.4,5)

show secondary follicle with C-shaped antrum, In addition to having more granulosa cells and a larger size, secondary follicles also have stromal tissue around them that is divided into internal and external thecal layers. secondary follicles oocyte surrounded by granulosa cells multiple later based on zona pellucida (fig.5)

atretic follicles were classified follows: Stage I, degenerative changes are present only in the granulosa wall which shows cell shrinkage, pyknosis, and karyorrhexis. At this stage the follicles are still spherical or ovoid. Stage II, changes are also present in the oocyte which shows signs of the resumption of meiosis, such as the breakdown of the nuclear membrane with or without the formation of a pseudomaturation spindle, and oocyte fragmentation. In antral follicles, the oocytes are able to resume meiosis spontaneously after the granulosa cells degenerate. At this stage, most follicles show deformities (fig.7,8).

Discussion

The present study revealed that the ovarian growth in the cortex layer specially in the follicles had many type according to the developments stage (primordial follicles, primary follicles, secondary follicles, tertiary follicles and mature Graafian follicles, and this is the healthy process of the ovarian tissue.The ovaries in cattle (Britt,. 2008) and sheep(Sreenivas et al., 2014), it was

concluded that antral follicle numbers increased transiently, or were high, early in life, but subsequently declined and remained relatively stable until puberty. In the current study the ovary has two main region the outer cortex and inner medulla. Epithelium covering ovary, made of saqumous epithelial cells. Tunica albuginea Outer dense, collagenous connective tissue layer covering the entire ovary, which is continuous with the peritoneal lining. Consist of a single layer of cuboidal epithelial cells called the germinal epithelium, which serve to prevent adhesions and is broken at ovulation this result agreement with (William and Linda, 2000) in cattle.

In the cortex layer characterized by The presence of large number of atretic follicles in the ovarian tissue due to insufficient gonadotrophins secretion (Wolfenson et al., 1995)

Different type of follicles in vaious stages of development are embedded in the stroma of the cortex, the most numerous are primordial follicles found in peripheral zone of the cortex just under the tunica albuginea, they are the smallest and simplest in structure surrounded by a single layer of granulosa cells primary follicles grows larger from resting individual primordial follicles, become cuboidal comprise a single surrounding layer. In various parts can be identified the thecae surrounding the follicle into two portion an inner vascularized layer, the theca interna, and an outer fibrous connective tissue, the theca extern, the stratum granulosum or membrane granulosa, the large antrum filled with follicular fluid and the cumulus oophorus in which is embedded the ovum, smaller follicles with stratified follicular cells surrounding the ovum are growing follicles, the ovum is small in primary follicles then increases gradually in size in growing follicles . Secondary follicle they contain two or more layers of granulosa cells, oocyte continue to enlarge and forms zona pellucida , Tertiary follicle, fluid filled follicle visible on surface of the ovary typically have an antrum and forming cumulus oophorus , larger follicles with cavities of various sizes are termed vesicular follicles they are situated deeper in the cortex and are surrounded by connective tissue capsules , most of the follicles contain an ovum with its nucleus or germinal vesicle. An atertic follicle containing the remnants of a disintegrating ovum. These results are agreement with (Samuelson, 2007; Junqeira et al., 1998).

the medulla is vasculature and primarily loose stromal tissue, contains blood vessels and connective tissue these result agreement with (Junqeira et al., 1998) in sheep.

Conclusion: The Result of this study referring to the histological structure of the ovary in the female genital system ,Black goat follicles vary greatly in their characteristics during growth and development and atresia, it is necessary to develop criteria for classifying them. Ovarian follicles are the easiest to classify and, at nearly all stages of growth, four types of follicles can be identified; primordial follicles, primary, secondary and antral follicles. The atretic follicles were almost identical and these were characterized by presence of antrum and the granulosa cell notice droped and separated from each other into the antrum according to the type of atretic follicles.

Table :1	
Area	**Thickness**

Cortex	189.512±1.15 mm	Granulosa cell	Theca cell	Diameter of follicles	Diameter of oocyte
Medulla	94.21±1.21 mm				
primordial follicle		-	-	63.865±2.02mm	10.22±12.02mm
Primary follicles		-	-	88.27±14.21mm	44.31±17.05mm
Secondary follicle		8.14±2.04 mm	10.014±1.40mm	266.22±11.2mm	61.114±15.22 mm
Antral follicle		16.032±1.22 mm	22.115±22.10 mm	322.11±12.12 mm	75.22±17.12mm
Graffian follicle		24.12±2.011 mm	29.05±1.21mm	488.22±11.2m.	81.11±13.02mm

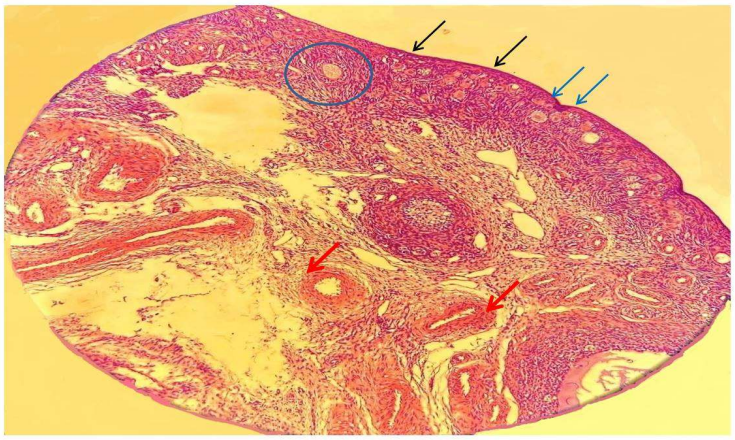

Fig. 1 Photograph of ovary in the goat show the: Surface epithelium (black arrow) cortical stroma with many primoidal &primary follicle (blue arrow) secondary follicle (blue circle) . Blood vissle (red arrow) H&E stain X100

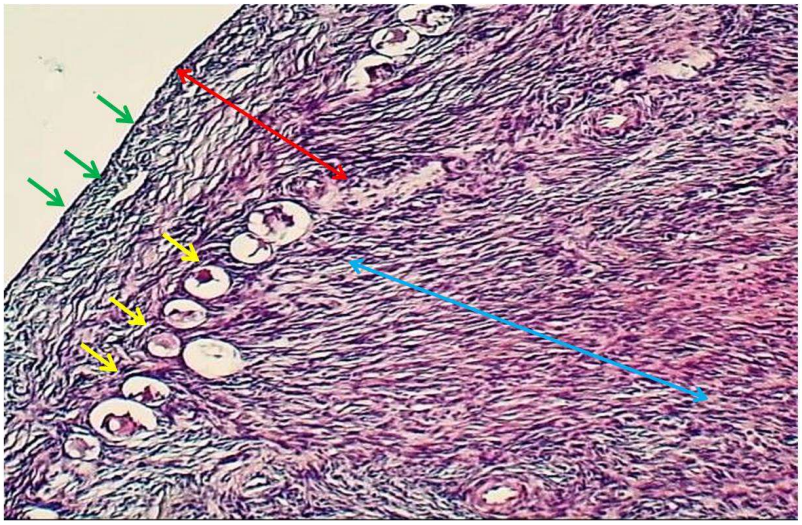

Fig. 2: Photograph of ovary in the goat show the germinal epithelium (green arrows) , cortex (red double arrow) ,containing primordial follicles (yellow arrows) medula (blue double arrow), (H&E X 100)

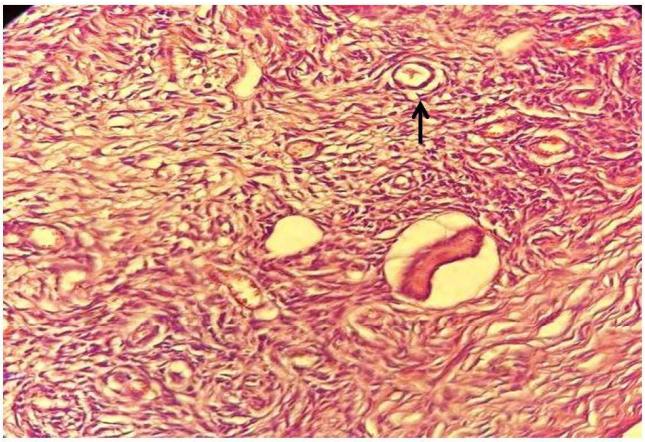

Fig. 3 Photograph of ovary in the goat show the: Primary follicles (black arroe arrow). H&E stain X 100

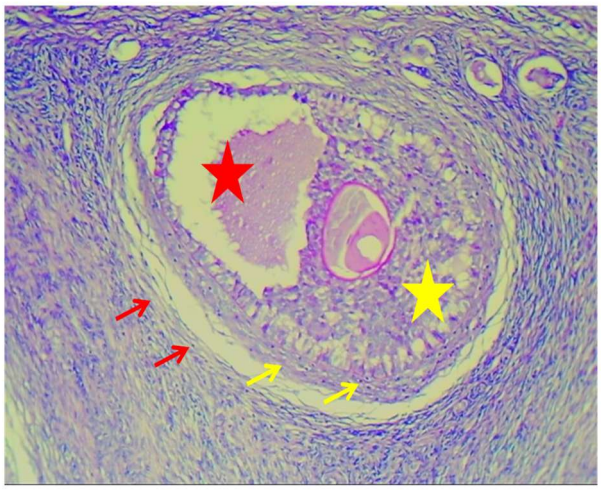

Fig.4: Photograph of ovary in the goat show: the antral follicles beginning antrum (red star) Gumulus oophorus with oocyte (yellow star) theca interna (yellow arrow)theca externa.(red arrow) H&E X400

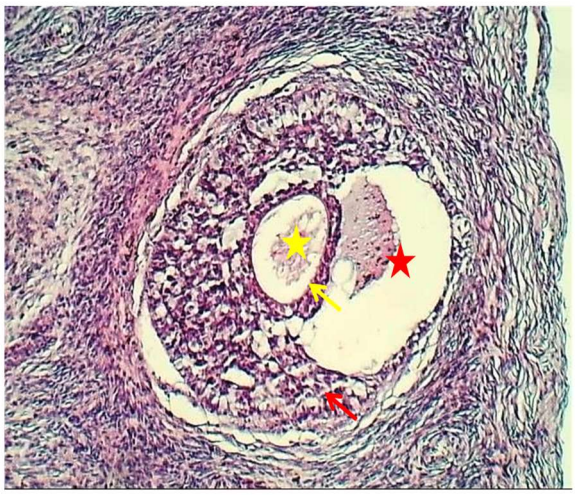

Fig. 5 Photograph of ovary in the goat show: Secondary follicles .zona pellucida (yellow arrow) oocyte (yellow star) ,antrum (red star) granulosa cell (red arrow). H&E stain X 400

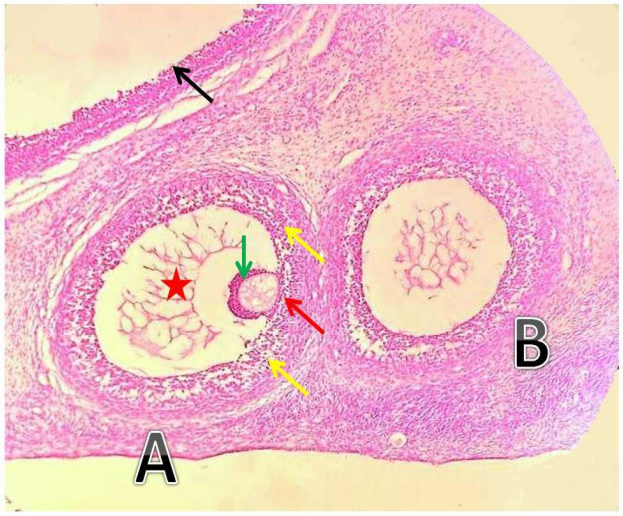

Fig.6 Photograph of ovary in the goat show Graffian follicle (A) corona radiate (green arrows) ,commulus oopherus (red arrow) ,antrum (red star) granulosa (yellow arrows) , germinal epithelia black arrow .secondary follicles (B) (H&E X 100)

Fig. 7 Photograph of ovary in the goat show the: Atertic follicles granulosa cells droped into the antrum (red star). theca interna (black arrow) theca externa H&E X400

Fig. 8 Photograph of ovary in the goat show the: Atertic follicles ,commulus oopherus (red arrow) ,antrum (black star) granulosa (yellow arrows) , germinal epithelia black arrow . (H&E X 400)

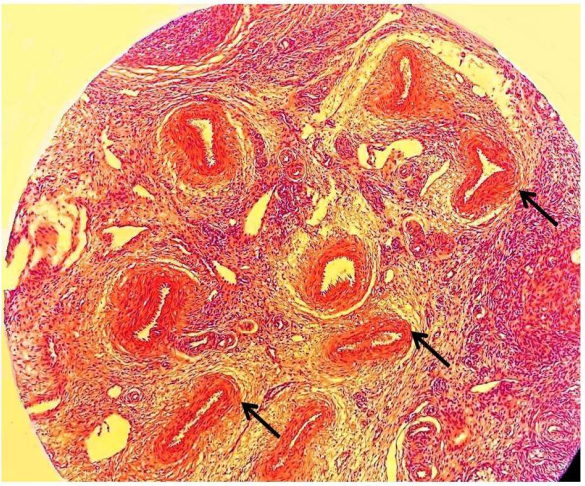

Fig.9 Photograph of medulla in the ovary of goat showed blood vessels black arrow &connective tissue H&E stain x100

Conclusion: The Result of this study referring to the histological structure of the ovary in the female genital system of goat.The atretic follicles were almost identical and these were characterized by presence of antrum and the granulosa cell notice droped and separated from each other into the antrum according to the type of atretic follicles.

Reference

Al-Khazraji1.K.I., Eesa M. J. and Merhesh. S. M.,(2016) the effect of laparoscopic unilateral ovariectomy in young Iraqi black goat on the histomorphometric of the remaining ovary at adult stage. Iraqi J. Vet. Med. Vol. 40 No. 104-107

Alwan, A.F.(2014). Fetal adrenal cortex development with maternal serum cortisol profile in relation to estrous induction, laparoscopical insemination in Iraqi goats out breeding season. Iraqi J. Vet. Med. 38(1): 129-136.

Banks WJ (1993): Female reproductive system. Applied Veterinary Histology. Mosby, St. Louis.

Bari, M. A.; Kabir, M. E.; Sarker, M .B. and Moniruzzaman, M. (2011): "Morphometric analysis of ovarian follicles of Black Bengal goats during winter and summer season" .Department of Animal Science, Bangladesh Agricultural University, Mymensingh 2202, and Bangladesh. Bangladesh Animal Husbandry Association. Bang. J. Anim. Sci., 39(1-2): 51-55.

Britt, J.H. 2008. Oocyte development in cattle: physiological and genetic aspects. Revista Brasileira de Zootecnia. 37: pp 110-115.

Camp, J.C., Wildt, D.E., Howard, P.K., Stuart, L.D., Chakraborty, P.K. (1983). Ovarian activity during normal and abnormal length estrous cycles in the goat. Biol Reprod. 28, 673-681. https://doi.org/10.1095/biolreprod28.3.673 PMid:6221766

de Castro, T., Rubianes, E., Menchaca, A., Rivero, A. (1999). Ovarian dynamics, serum estradiol and progesterone concentrations during the interovulatory interval in goats. Theriogenology 52, 399-411.

Dyce, K.M Sack, W.O. and Wensing, C. J.(2010).Text book of Veterinary Anatomy published in China library of Congress cataloging in. WB Saunders Comp.pp701.

Evans, A.C.O. (2003). Characteristics of ovarian follicle development in domestic animals. Reprod Dom Anim. 38, 240-246.

Haqu Z, Haque A. Abul Quasem MD(2015). Gross and histomorphology of the ovary of Black Bengal Goat (Capra hircus). MJVR; 7(1): 37–42.

Jennigs R, Premanandan C (2017): Veterinary Histology. The Ohio State University, Columbus, USD.

Junqeira, Luis Carlos, Jose Carneiro, Robert O. Kelley. (1998).Basic Histology. Ninth. Stamford, Connecticut: Appleton & Lange.

Kaymaz M, Fındık M, Rişvanlı A, et al (2013): Obstetric and Gynecology in Cats and Dogs. Medipres, Malatya.

Kennedy, J.P., Worthington, C.A., Cole, E.R., 1974. The post-natal development of the ovary and uterus of the Merino Lamb. J. Reprod. Fertil. 36, 275–282.

Luna, I.G. (1968): Manual of histology staining methods of the armed force institute of pathology. 3rd ed. McGraw-Hill book Company New York.

McEntee K (1990): Reproductive Pathology of Domestic Mammals. Academic Press, New York.

Mustafa, A.R. and Ali F.Reshag.(2019)Histological Study on the Nasal Cavity of Black Iraqi Goat (Capra hircus) Iraqi J. Vet. Med. Vol. 42 No. 2 105-111 pp

Özer, A. (2010). Veterinary Special Histology. Extended 2th ed. Bursa, Turkey: Nobel Publishing.

Saif,M.H., and Farhan,O.R. (2019). Histomorphological and hormonal study of genital system in albino female rats at different ages.JGPT.PP318-323

Samuelson, D. A. (2007).Text of veterinary histology.PP.230.

Shively, M. J. (1984).Veterinary Anatomy Basic, comparative, And Clinical.texas A&M University press college stationPp :363-365.

Smith, M.C. and Sharman, D.M. (2009). Goat medicine. 2nd ed . Wiley-Blackwell. Singapore. pp : 3-4.

Songsasen, N.; Fickes, A.; Pukazhenthi, B.S. and Wildt, D.E. (2009). Follicular morphology, oocyte diameter and localization of fibroblast growth factors in the domestic dog ovary. Reprod. Domest. Anim. 44(Suppl 2): 65–70.

Sreenivas, D., DSVGK, K., Yarla, N.S., Thomas, V.M., PalniSamy, A., Vadlapudi, V.R. and Preethi, R., 2014. In vitro production ofsheep embryos in CR1aa medium supplemented with L-Ascorbic Acid. Journal of Tissue Science and Engineering. 5: pp 131-136.

William J and Linda M. (2000).Color Atlas of Veterinary Histology, Second Edition (1Philadelphia • Baltimore • New York • London.

William JB (1986): Female reproductive system. Applied Veterinary Histology. Williams and Wilkins, London.

Wolfenson, D.; Thatcher, W.W.; Badinga, L.; Savio, J.D.; Meidan, R.; Lew, B.J.; Braw-Tal, R. and Berman, A. (1995). Effect of heat stress on follicular development during the estrous cycle in lactating dairy cattle. Biol. Reprod. 52: 1106-1113